

## Letters

### OBSERVATION

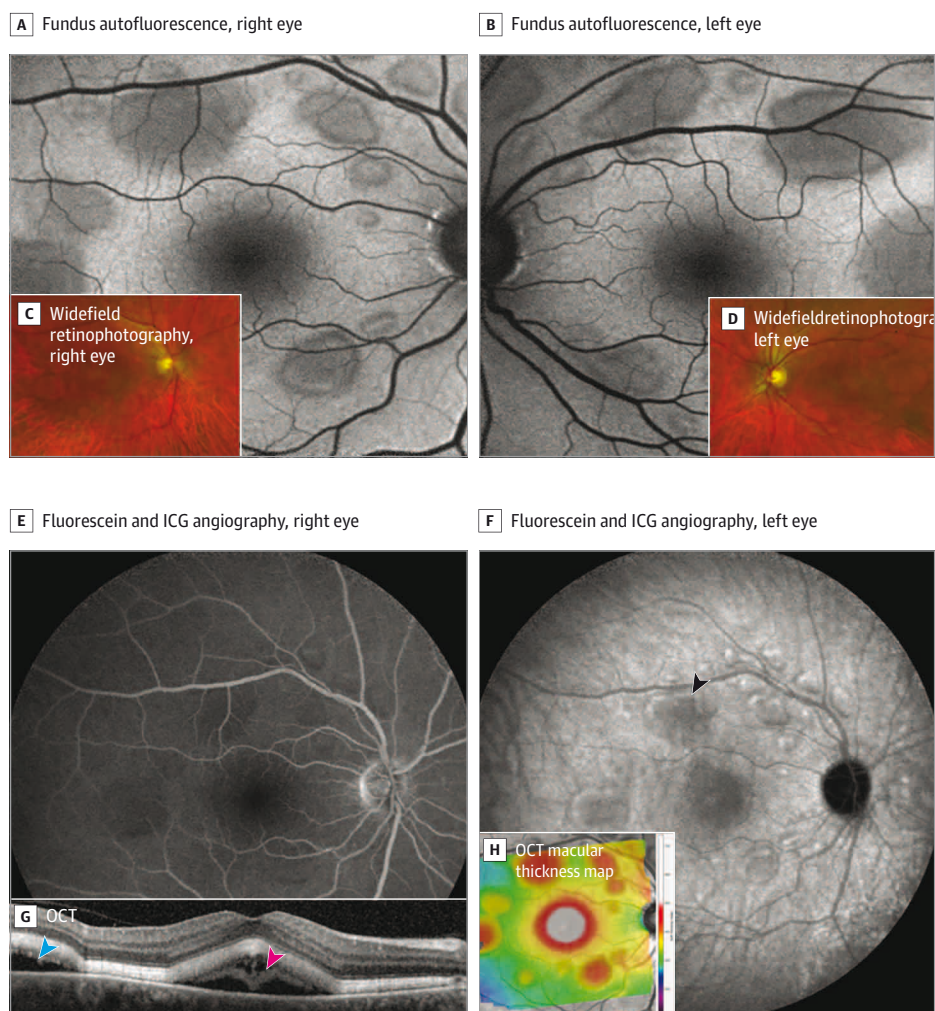
#### Retinopathy Associated With Hair Dye

Retinopathy associated with the use of hair dye aromatic amines (RAHDAA) was recently reported in 3 middle-aged women following exposure to hair dyes containing aromatic amines.<sup>1</sup> It was described as multiple bilateral serous retinal detachments (SRDs) mimicking MEK inhibitor-associated retinopathy, involving the mitogen-activated protein kinases kinase enzymes MEK1, MEK2, or both. The retinopathy resolved within months after discontinuing the hair dye.

**Report of a Case** | A 61-year-old woman with no medical history presented with bilateral blurry vision a few days after dyeing her hair with hair dye containing aromatic amines. The patient used a commercially available hair dye that contained aromatic amines called para-phenylenediamine. She reported no exposure to corticosteroids.

Visual acuity was 20/40 in the right eye and 20/20 in the left eye. Fundus examination revealed bilateral multiple SRDs located primarily in the posterior pole (**Figure 1**). Optical coherence tomography (OCT) imaging revealed multiple SRDs and diffuse thickening of the neurosensory retina. Choroidal thickness

Figure 1. Baseline Presentation of Bilateral Retinopathy Associated With the Use of Hair Dye Aromatic Amines

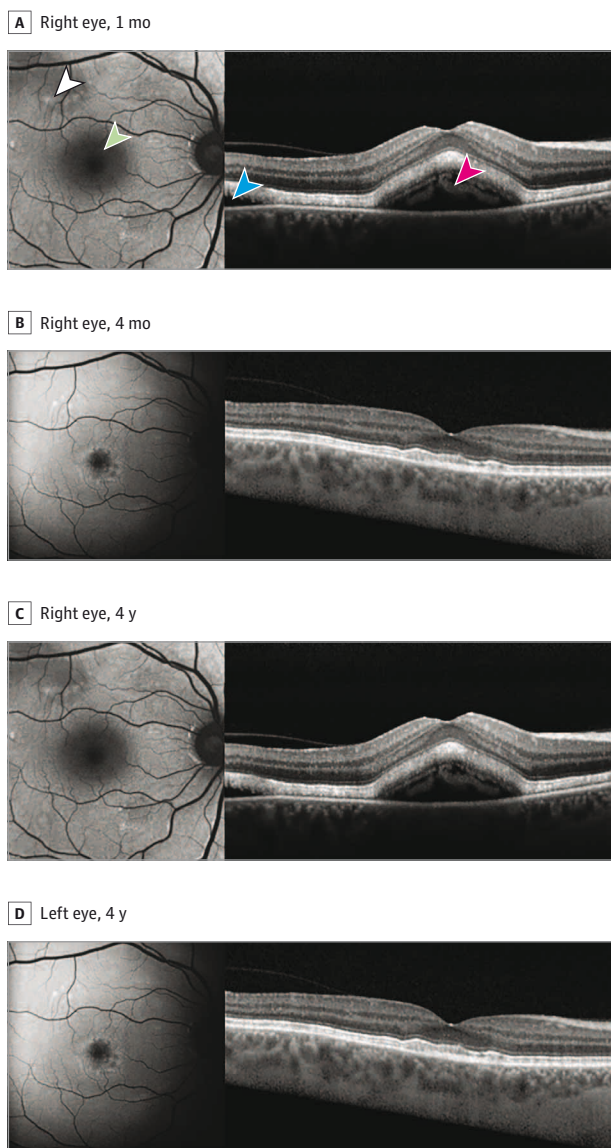


A and B, Fundus autofluorescence showing hypoautofluorescent serous retinal detachments (SRDs) at baseline. C and D, Widefield retinophotography showing bilateral multiple SRDs. E and F, Fluorescein and indocyanine green (ICG) angiography at 20 minutes showing no leakage points or vasculitis; the SRDs did not stain during the angiographic sequence. ICG angiography revealed

neither abnormally dilated choroidal vessels nor choroidal diffusion. The black arrowhead indicates an SRD. G, Optical coherence tomography (OCT) showing SRDs (blue arrowhead) and subfoveal thickening of the neurosensory retina (pink arrowhead). H, OCT macular thickness map showing the increased thickness associated with the SRDs.

Letters

**Figure 2. Autofluorescence and Spectral-Domain Optical Coherence Tomography Follow-Up of the Right Eye**



A, Right eye at 1 month. B, Right eye at 4 months. C, Right eye at 4 years. D, Left eye at 4 years. At 1 month, autofluorescence shows hyperautofluorescent areas (white arrowhead) and a macular hypoautofluorescent area corresponding to the serous retinal detachment (green arrowhead). Spectral-domain optical coherence tomography confirms a serous retinal detachment (blue arrowhead) and a thickening of the neurosensory retina (pink arrowhead). In resolved serous retinal detachment areas, hyperautofluorescent subretinal material persisted at 4-year follow-up.

through the fovea was 250  $\mu\text{m}$ , with no pigment epithelium detachment or abnormally dilated choroidal vessels that might be associated with central serous chorioretinopathy. Fundus autofluorescence showed hypoautofluorescent SRDs.

Fluorescein angiography showed no leakage or vasculitis and the SRDs did not stain during the angiographic sequence. Indocyanine green angiography revealed neither abnormally dilated choroidal vessels nor choroidal diffusion (Figure 1).

An extensive etiological assessment was conducted, including comprehensive blood tests and chest computed tomography scan to exclude sarcoidosis, brain magnetic resonance imaging and anterior chamber tap interleukin 6/10 assay to rule out oculocerebral lymphoma, and positron emission tomography scan, mammogram, and dermatological and gynecological examination to investigate a potential acute exudative polymorphous vitelliform maculopathy. All tests yielded normal results. RAHDAA was diagnosed based on the temporal association between symptoms and hair dye exposure, consistent with the description including OCT appearance (multiple SRDs predominantly located in the posterior pole and neurosensory retina thickening).<sup>1</sup>

Four months later, visual acuity was 20/20. Fundus examination showed complete resolution of the SRDs. OCT revealed subretinal deposits that were hyperautofluorescent, without any residual SRD (Figure 2).

Four years later, the patient reported using aromatic amines-free hair dye and has not experienced any recurrence. Visual acuity remained 20/20, though subretinal deposits persisted (Figure 2).

**Discussion |** RAHDAA presumably is a rare condition. Its presentation closely resembles MEK inhibitor-associated retinopathy.<sup>2-4</sup> It should be considered a diagnosis of exclusion after other potential diagnoses including central serous chorioretinopathy have been ruled out.

The retinal toxicity mechanism of anti-MEK agents appears to involve inhibition of the fibroblast growth factor receptor mitogen-activated protein kinase pathway (FGFR-MAPK) in retinal pigment epithelial (RPE) cells.<sup>3</sup> Para-phenylenediamine, found in hair dye, may disrupt the MAPK pathway, potentially explaining the similarities between these 2 retinopathies.<sup>5</sup> This pathway is involved in the survival and homeostasis of RPE cells. Its alteration presumably could be associated with RPE dysfunction to explain the clinical signs.<sup>6</sup> Any scalp lesions might facilitate the systemic absorption of aromatic amines and perhaps account, in part, for the presumed rarity of this abnormality. However, no scalp wounds have been observed in the described cases.

This case of retinopathy associated with hair dye containing aromatic amines, with relatively long follow-up, shows persistent OCT abnormalities, hyperautofluorescent subretinal deposits 4 years after exposure removal, and a slow regression of the neurosensory retina thickening. This thickening might be secondary to intermittent RPE dysfunction, which suggests aromatic amines could be responsible for long-lasting RPE dysfunction. The absence of recurrence after switching to aromatic amines-free dyes strengthens the association between para-phenylenediamine and RAHDAA. A functional impact assessment of these lesions using microperimetry could not be performed at our site but might be interesting.

RAHDAA may be rare or underdiagnosed. However, identifying this pathology may allow prompt consideration to remove exposure to such hair dye in an attempt to limit persistent RPE damage.

Nicolas Chirpaz, MD  
Marion Bricout, MD  
Sandra Elbany, MD  
Olivier Loria, MD  
Antonin Rocher, MD  
Carole Burillon, MD, PhD  
Corinne Dot, MD, PhD

**Author Affiliations:** Ophthalmology Department, Edouard Herriot Hospital, Hospices Civils de Lyon, Lyon, France (Chirpaz, Bricout, Elbany, Rocher, Burillon, Dot); LEO Ophthalmologic Center, Private Hospital of Eastern Lyon, Saint-Priest, France (Loria); Claude Bernard Lyon 1 University, Lyon, France (Burillon); Military Health Service Academy, Val-de-Grâce, Paris, France (Dot).

**Corresponding Author:** Nicolas Chirpaz, Burillon's Ophthalmology Department, Edouard Herriot Hospital, Five Place d'Arsonval, Lyon 69003, France (nicolas.chirpaz@chu-lyon.fr).

**Published Online:** September 12, 2024. doi:10.1001/jamaophthalmol.2024.3453

**Conflict of Interest Disclosures:** Dr Dot reported personal fees from Bayer, AbbVie, Novartis, Roche, and Horus Pharma. No other disclosures were reported.

**Additional Contributions:** We thank the patient for granting permission to publish this information.

1. Faure C, Salamé N, Cahuzac A, Mauget-Fàysse M, Scemama C. Hair dye-induced retinopathy mimicking MEK-inhibitor retinopathy. *Retin Cases Brief Rep.* 2022;16(3):329-332. doi:10.1097/ICB.0000000000000969
2. Murata C, Murakami Y, Fukui T, Shimokawa S, Sonoda KH, Fujisawa K. Serous retinal detachment without leakage on fluorescein/indocyanine angiography in MEK inhibitor-associated retinopathy. *Case Rep Ophthalmol.* 2022;13(2):542-549. doi:10.1159/000524558
3. Méndez-Martínez S, Calvo P, Ruiz-Moreno O, et al. Ocular adverse events associated with MEK inhibitors. *Retina.* 2019;39(8):1435-1450. doi:10.1097/IAE.0000000000002451
4. Duncan KE, Chang LY, Patronas M. MEK inhibitors: a new class of chemotherapeutic agents with ocular toxicity. *Eye (Lond).* 2015;29(8):1003-1012. doi:10.1038/eye.2015.82
5. Chong HP, Reena K, Ng KY, Koh RY, Ng CH, Chye SM. Para-phenylenediamine containing hair dye: an overview of mutagenicity, carcinogenicity and toxicity. *J Environ Anal Toxicol.* 2016;6. doi:10.4172/2161-0525.1000403
6. van der Noll R, Leijen S, Neuteboom GHG, Beijnen JH, Schellens JH. Effect of inhibition of the FGFR-MAPK signaling pathway on the development of ocular toxicities. *Cancer Treat Rev.* 2013;39(6):664-672. doi:10.1016/j.ctrv.2013.01.003